#53107

October 7-11 • San Diego, CA • www.idweek.org
IDWeek 2015
Advancing Science, Improving Care

GORGAS
INSTITUTO CONMEMORATIVO GORGAS DE ESTUDIOS DE LA SALUD
Email: jsuarez@gorgas.gob.pa

Dermatitis due to *Paederus sp.:* Report of an outbreak of 68 cases in the province of Darien, Panama

José Antonio Suárez, MD[1], Lorenzo Caceres, PhD[1], Carmela Jackman, MD[2], Amanda M. Gabster, MSc[1], Panamá Peréz, MD[2], Juan Miguel Pascale, MD, PhD[1] and Néstor Sosa, MD[1],
(1)Gorgas Memorial Institute for Health Studies, Panama City, Panama, (2)Ministry of Health of Panama, Metetí, Panama

1.-Background: *Paederus spp*. dermatitis is a form of irritant contact dermatitis caused by the accidental exposure to rove beetles. It is characterized by the sudden onset of erythematous and vesicular cutaneous lesions with burning sensation on exposed areas of the body. The disease is provoked by pederin release from the endolymph of *Paederus* beetles, class *Insecta*, order *Coleoptera*, family *Staphylinidae*.
The diagnosis is supported by the characteristic lineal or mirror image lesions, accompanied by the history of exposure to the insect.

Paederus spp

2.-Methods: We present a descriptive clinical and epidemiological study of an outbreak of contact dermatitis caused by *Paederus spp.* in the province of Darien, Panama. After an initial report of 10 cases of an unusual type of dermatitis in different healthcare facilities, a case definition was established.
The etiology of Paederus contact dermatitis was suspected. A retrospective clinical chart review was undertaken and a clinical epidemiological questionnaire was applied in 20 communities to look for additional cases that had not been seen in the health centers. A team of entomologists visited the affected communities to capture and characterize the implicated insects for three consecutive days.

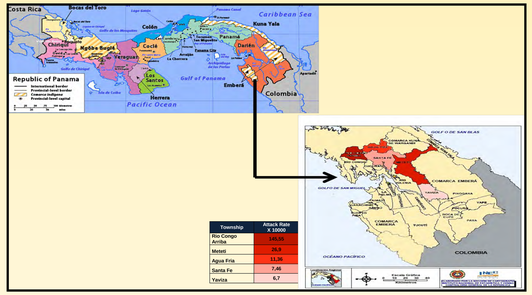

3.-Results: During April to July 2014 a total of 68 cases of Paederus irritant contact dermatitis were reported in 20 communities. Fifty three percent of those affected were females. The age group of 0 to 5 years had the highest absolute number of cases with 15 (22.1%). The most common clinical presentation was classical linear dermatitis, found in 58.1% (25/43) of the subjects. In 41.9% (18/43), mirror image lesions were reported; the rest had multiple vesicular-pustular lesions and crusted lesions. The most common symptoms were burning sensation in 65.1% (28/43), pruritus in 60.4%(26/43); pain in 25.6%(11/43) and fever in 9.3%(4/43). In 39.53% (17/43) of the subjects, the lesions were located in the face and/or neck. Eighty-one specimens of *Paederus spp* were collected, 68.0% (55/81) of them from peridomicilary areas.

Clinical Presentation

Linear dermatitis lesion

Mirror Image lesion

Vesicular-pustular lesion

Lid edema

Crusted lesion

4.-Conclusion: This *Paederus spp* dermatitis report represents one of the largest outbreak described in Latin America.
Linear dermatitis and mirror image lesions are indeed a frequent characteristic of the exposure to *Paederus spp*.

5.-Acknowledge: Entomology Section of Gorgas Memorial Institute for Health Studies

6.-References:1.-Vidal Haddad, Jr, MD, PhD,a Jo~ao Luiz Costa Cardoso, MD et al. Tropical Dermatology: Venomous Atrhropods and Human Skin. Vol 67 number 3, J Am Acad Dermatol. September 2012.
2.- Cressey BD, Paniz-Mondolfi AE, Rodríguez-Morales AJ, Ayala JM, De Ascenção Da Silva AA. Dermatitis linearis: vesicating dermatosis caused by paederus species (coleoptera: staphylinidae). Case series and review. Wilderness Environ Med. 2013; 24:124-31. doi: 10.1016/j.wem.2012.11.005. Epub 2013 Jan 24. Review