Presentation no. 1111

Cleveland Clinic

Histopathological Findings in Infective Endocarditis

Dylan Ely, BA[1], Carmela D. Tan, MD[2], E. Rene Rodriguez, MD[2], Syed T. Hussain, MD[3], Gosta B. Pettersson, MD, PhD[3], Steven M. Gordon, MD[4], Nabin K. Shrestha, MD, MPH[4]

[1]Case Western Reserve University School of Medicine, and Departments of [2]Pathology, [3]Cardiothoracic Surgery, and [4]Infectious Diseases Cleveland Clinic, Cleveland, OH, USA

Nabin K. Shrestha, MD
9500 Euclid Avenue / G-21,
Cleveland, OH 44195
Tel: 216-444-1687
Fax: 216-445-9446
Email: shrestn@ccf.org

Abstract

Background: Cardiac valves excised from patients with either confirmed or suspected infective endocarditis (IE) are routinely sent for histopathological analysis. However, only a few studies describe the histopathological findings in such valves, and these studies have limitations. The purpose of this study was to examine and describe these findings in a large cohort.
Methods: Episodes of IE that were operated on between July 1, 2007 and July 1, 2014 were selected for this study. IE was defined as meeting Duke Criteria for definite IE. Surgical pathology reports for the identified patients were analyzed for the presence of polymorphonuclear leukocytes (PMNs), lymphocytes, histiocytes, foamy histiocytes, neovascularization, giant cells, fibrin deposits, and microorganisms on special staining. Co-occurrence of histopathological findings was examined using hierarchical cluster analysis.
Results: Of 862 valves sent for histopathological examination, 41 were excluded because only gross examination was done. The remaining 821 valves came from 703 episodes of IE in 679 patients. The majority (59%) were native valves. Bovine pericardial valves were the most common prosthetic valves (46% of prosthetic valves). Microorganisms, fibrin deposits, and PMNs, were seen in 67%, 61%, and 56% of valves, respectively. There was stepwise clustering of histopathological findings along the sequence: microorganisms / fibrin deposits, PMNs, neovascularization, lymphocytes, histiocytes / foamy histiocytes, giant cells, and fibrosis (figure 2), but no clustering by valve type, valve position, microorganism or the reading pathologist. 82% of IE episodes had acute inflammation (presence of PMNs or fibrin deposits), 66% had chronic inflammation (neovascularization, lymphocytes, histiocytes, foamy histiocytes, or giant cells), and 96% had acute / chronic inflammation or microorganisms. Microorganisms were seen in 58%, 52%, and 34% of IE episodes, respectively, on Gram, Gomori methenamine silver, and periodic acid Schiff staining.
Conclusions: Inflammation or microorganisms can be detected in the majority of patients (96%) with infective endocarditis, thus establishing a definite diagnosis of infective endocarditis. All valves removed at surgery should be examined histologically, and absence of inflammation or microorganisms should cast doubt on a diagnosis of IE.

Introduction

- Cardiac valves excised from patients with either confirmed or suspected IE are routinely sent for histopathological analysis
- However, there are no studies that describe the histopathological findings in such valves in a large series of patients. The purpose of this study was to examine and describe these findings

Methods

- Episodes of surgically-treated IE, operated on between July 1, 2007 and July 1, 2014, were identified from the Cleveland Clinic Infective Endocarditis Registry
- IE was defined as meeting Duke Criteria for definite IE
- Pathology reports were reviewed and specific data elements extracted by manual chart review
- Co-occurrence of histopathological findings was examined using hierarchical cluster analysis

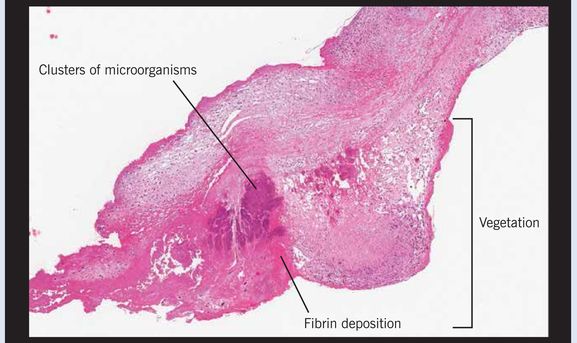

Figure 1. Representative picture showing some of the histopathological findings in a valve excised from a patient with IE

Results

- In the time period studied, of 862 valves submitted 41 were excluded because only a gross examination (no histopathological examination) was done. The remaining 821 valves from 703 episodes of IE in 679 patients were included.
- Of the 821 valves, 470 (57.2%) were aortic, 291 (35.4%) mitral, 5 (0.6%) pulmonic, and 55 (6.7%) tricuspid valves
- There were 484 (59.0%) native valves, 30 (3.7%) bioprosthetic, 155 (18.9%) bovine pericardial, 60 (7.3%) porcine, 30 (3.7%) homografts, and 62 (7.6%) mechanical valves

Distribution of individual pathological findings

Table 1. Distribution of individual histopathological findings in the 821 included valves.

Characteristic	Frequency n (%)
Microorganisms	549 (67)
Fibrin deposits	503 (61)
Polymorphonuclear leukocytes	463 (56)
Neovascularization	349 (43)
Histiocytes	263 (32)
Fibrosis	263 (32)
Lymphocytes	250 (30)
Foamy histiocytes	130 (16)
Giant cells	112 (14)

Clustering of pathological findings

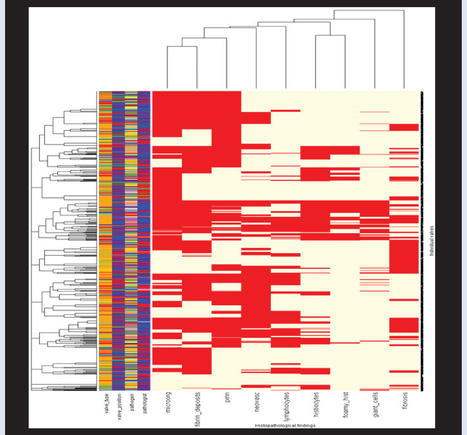

Figure 2. Heat map showing the clustering of all 821 valves and 9 histopathological findings. Each column in the heat map represents one histopathological finding and each row corresponds to an individual valve. Red indicates the finding was present, yellow that it was absent.

Acute and chronic inflammation, and repair

Based on the clustering patterns, acute inflammation was defined as presence of fibrin deposits or PMNs. Chronic inflammation was defined as presence of neovascularization, lymphocytes, histiocytes, foamy histiocytes or giant cells. Tissue repair was defined as presence of fibrosis.

Table 2. Frequencies of acute and chronic inflammation and repair

Characteristic	Frequency n (%)
Microorganisms seen	504 (72)
Acute inflammation	574 (82)
Chronic inflammation	467 (66)
Inflammation (acute or chronic)	633 (90)
Both acute inflammation and chronic inflammation	408 (58)
Tissue repair	238 (35)
Inflammation or repair	658 (94)
Inflammation and repair	223 (32)
Acute inflammation or microorganisms	645 (92)
Inflammation or microorganisms	674 (96)

Staining of microorganisms with special stains

Table 3. Detection of microorganisms by different stains in at least one valve in 703 episodes of IE

Stain	Frequency n (%)
Gram stain	405 (58%)
Gomori methenamine silver stain	369 (52%)
PAS stain	240 (34%)

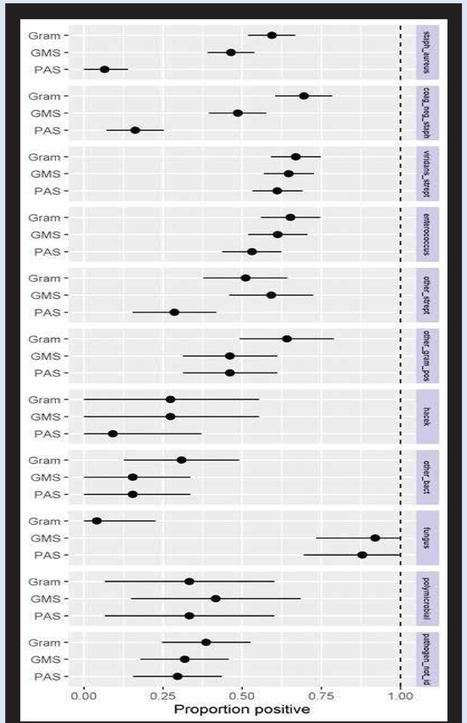

Figure 3. Performance of various special stains in detecting microorganisms in histopathological specimens, for different microorganisms. The error bars represent two standard errors on each side.

Conclusions

Inflammation or microorganisms can be detected in the majority of patients (96%) with infective endocarditis, thus establishing a definite diagnosis of infective endocarditis.

All valves removed at surgery should be examined histologically, and absence of inflammation or microorganisms should cast doubt on a diagnosis of IE.