Prosthetic joint osteomyelitis due to *Brucella melitensis* fifteen years after knee prosthesis placement

Andrea Cárdenas-Ortega, MD[1], Patricia Volkow-Fernández , MD[1]

[1] Instituto Nacional de Cancerología, Infectious Diseases Department

Andrea Cárdenas-Ortega, MD
Infectious Diseases Fellow, Instituto Nacional de Cancerología
Av. San Fernando #22, Sección XVI, Tlalpan, Ciudad de México 14080
Phone +521 5527276409
Email: andie.cardeo@gmail.com

Patricia Volkow Fernández, MD
Infectious Diseases Department, Instituto Nacional de Cancerología
Av. San Fernando #22, Sección XVI, Ciudad de México 14080
Phone +521 551026450
Email: pvolkow@gmail.com

Background

Brucellosis is the most common zoonosis worldwide. There are 500,000 cases reported annualy.[1] The major endemic areas are the Mediterranean basin, Persian Gulf, Indian subcontinent, Mexico, and Central and South America.[2] Acute illness may present with fever, night sweats, myalgias and arthralgias. It is an important cause of fever of unknown origin, yet 30% present with a localized infection. Osteoarticular involvement, mainly lower limbs and sacroiliac joints are the most commonly affected. Myocarditis, pericarditis and endartheritis are deadly complications. Chronic illness may present as intermittent back pain, arthralgias, night sweats and psychoneurosis. It may be complicated with spondylitis and may develop paravertebral, epidural or psoas abscesses. Few prosthetic joint infection cases have been described worldwide.[3]

Clinical case presentation

- A 48 year old male from Central Mexico presented with a two month history of erythema, swelling and increasing pain of the left knee that limited him from standing up or walking, attributed to prosthetic loosening. He referred occasional fever spikes without chills. The patient underwent surgery; prosthesis was removed and replaced with a medicated cemented spacer. Purulent exudate was obtained for microbiological analysis.-
- History of a distal femur giant cell tumor treated surgically with a prosthetic replacement of the left knee fifteen years before.
- Worked as a goat breeder and consumed non-pasteurized dairy products.
- Physical examination revealed a pleasant, robust male, without respiratory distress, weight loss or paleness. The blood pressure was 130/80 mmHg, pulse 82 beats per minute, temperature 98.6°F (37°C) and 19 breaths per minute. The left knee appeared swollen and warm, spontaneously painful, non-fluctuating, the surgical scar had no abnormalities and the knee movements were limited. The rest of the physical examination was otherwise normal.

Laboratory results

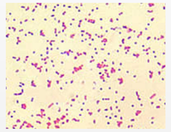

Figure 1. Secretion culture gram stain showing gram variable cocobacillar structures
(Courtesy of Microbiology Laboratory INCan)

WBC	12.7 x10^3 cells/mm^3	4.8—10.8 x10^3 cells/mm^3
Total neutrophils	9.9 x10^3 cells/mm^3	1.4—6.5x10^3 cells/mm^3
Total lymphocytes	1.5 x10^3 cells/mm^3	0.1—0.6 x10^3 cells/mm^3
Haemoglobin	12.3 g/dL	12—16 g/dL
Hematocrit	36.3%	37%—47%
Platelets	271 x10^3 cells/mm^3	130—400 x10^3 cells/mm^3
C-reactive protein	1.68 mg/dL	0.02—0.9 mg/dL

- Other laboratory results were either negative or within normal range.
- Serology (ELISA) for *Brucella* positive 1:2
- PCR 16S rRNA *Brucella melitensis*

SPECT scan UBI—(99m)Tc

Figure 2. Increased radioisotope uptake at the distal portion of the left femur, patella and tibia

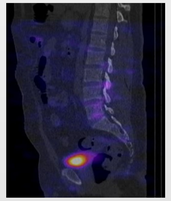

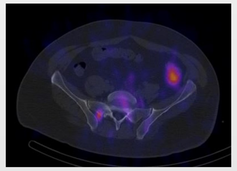

Figures 3 and 4. Radioisotope increased uptake at lumbar vertebrae (L3 - L5) and right sacroiliac joint, highly suggestive of spondylitis and osteomyelitis

Treatment and case evolution

Amikacyn 1 gram OD for 7 days plus Doxycyclin 100 miligrams BID for 8 weeks plus Rifampicin 300 mg TID <u>for 8 weeks</u>

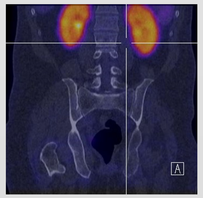

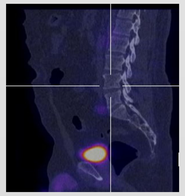

Figures 5 and 6. Follow-up lumbar and sacroiliac SPECT scan UBI (99m)TC performed 8 weeks after starting treatment. No radioisotope increased uptake at lumbar vertebrae and left sacroiliac joint

Discussion

Searching for epidemiological and risk factors on every patient, like work related or exposure to potentially infected cattle or its dairy products, as well as traveling to endemic areas are crucial for the diagnosis.[3] It should be considered in patients with clinical manifestations of chronic prosthetic joint infection whose microbiological diagnosis has been limited by conventional culture methods. MALDI-TOF has shown to be a useful diagnostic tool, however, the database in some countries is restricted and has not incorporated *Brucella* due to their potential bioterror threat potential. RT-PCR 16s rRNA and serologic tests can also be useful. Considering that only 30% present as a single site infection, it is imperative to practice a whole body molecular image study like SPECT UBI-Technetium 99 to investigate other sites of potential involvement. Triple antibiotic therapy has shown good response.[4]

Conclusions

In endemic zones, prosthetic joint infection due to *Brucella* should be considered regardless of the prosthesis' age. Every patient should be submitted to an extensive analysis screening for other sites of infection. SPECT scan UBI-Technetium 99 is a very helpful tool. In this case, treatment with aminoglycosides for one week plus Doxycycline 100 mg BID plus Rifampicin 300 mg TID for eight weeks and prosthetic removal had a positive impact on the clinical outcome and should be considered as a treatment strategy in cases similar to this case

References

1. Bosilkovski M, Dimzova M, Grozdanovski K. Natural History of Brucellosis In An Endemic Region In Different Time Periods. Acta Clin Croat 2009 Mar; 48(1): 41—6
2. Pappas G, Papadimitriou P, Akritidis N, et al. The New Global Map of Human Brucellosis. Lancet Infect Dis. 2006; (6(2):91 PMID 16439329
3. Domenica Flury, Behrend H, Sendi P, et al. *Brucella* melitensis Prosthetic Joint Infection. J Bone Joint Infect 2017; 2(3): 136 –142 PMID 28540150
4. Buzgan T, Karahocagil MK, Irmak H, et al. Clinical Manifestations And Complications in 1028 Cases of Brucellosis: A RetrospectiveEvaluation and Review of the Literature. Int J Infect Dis 2010 PMID 19910232

October 3-7 • San Francisco, CA • www.idweek.org
IDWeek 2016
Advancing Science, Improving Care